



ISSN Print: 2664-9659  
ISSN Online: 2664-9667  
Impact Factor: RJIF 5.46  
2023; 5(1): 05-08  
[www.hivjournal.com](http://www.hivjournal.com)  
Received: 11-01-2023  
Accepted: 23-02-2023

**Tarun Kumar**  
Reader, Department of Oral  
Medicine and Radiology,  
YIDDR, Yamunanagar,  
Haryana, India

**Neha Arora**  
Medical Officer (Dental), CHC,  
Pehowa, Department of  
Health and Family Welfare,  
Haryana, India

**Corresponding Author:**  
**Tarun Kumar**  
Reader, Department of Oral  
Medicine and Radiology,  
YIDDR, Yamunanagar,  
Haryana, India

## Candidiasis lesions in oral cavity in immune-compromised HIV positive patients: A review of literature

**Tarun Kumar and Neha Arora**

**DOI:** <https://doi.org/10.33545/26649659.2023.v5.i1a.4>

### Abstract

Oral manifestations are early clinical signs of Human Immunodeficiency Virus (HIV) infection since they can occur in more than half of HIV-infected patients and in up to three fourth of patients at the AIDS stage with  $<200$  CD4<sup>+</sup> T lymphocytes. Presence of some lesions can compromise dental aesthetics, chewing and swallowing, thus impacting the quality of life of patients. That is why, it is necessary to integrate, as part of the medical treatment of HIV-positive patients, the prevention, diagnosis, and control of oral health. It is essential that healthcare professionals have the power to identify, diagnose, and treat oral pathologies through clinical characteristics, etiological agents, and risk factors, both local and systemic.

**Keywords:** Oral manifestations, HIV, AIDS, candidiasis

### Introduction

The oral manifestations of HIV disease are manifold, prevalent, and clinically significant [1]. Although the recognition and management of HIV-related oral manifestations remains an important area of study for clinicians who provide medical care to persons with HIV, the referral of patients for routine and preventive dental care is equally important to maintaining patients' oral health and quality of life [1]. This topic will focus on common HIV-related oral conditions, including oral candidiasis, oral hairy leukoplakia, oral viral infections, ulcerative disease, malignancies and will also describe general oral health issues including periodontal and salivary gland findings among patients with HIV infection. The appropriate recognition of the injuries by doctors and dentists could generate an earlier and timelier referral to the HIV/AIDS treatment service or vice versa.

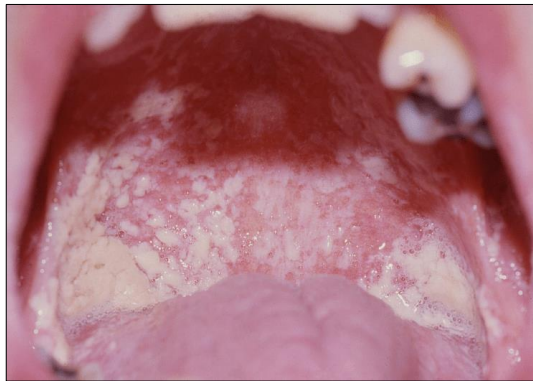Oropharyngeal candidiasis is seen frequently among individuals with HIV and is an indicator of immune suppression [2, 3]. It occurs most often in patients with CD4 cell counts less than 200 cells/mm<sup>3</sup>. *Candida albicans* is the most common species involved, but non-albicans species (*C. dubliniensis*, *C. glabrata*, *C. tropicalis*) can also cause disease [4]. The introduction and widespread use of effective antiretroviral therapy has led to a marked decrease in the prevalence of oral candidiasis. Although HIV-related immune suppression is typically the most important risk factor for developing oral candidiasis, other causes for oral candidiasis include antibiotic use, corticosteroids, chemotherapeutic drugs, and diabetes. By maximizing immune status with effective antiretroviral therapy, most cases of candidiasis can be avoided.

### Clinical manifestations

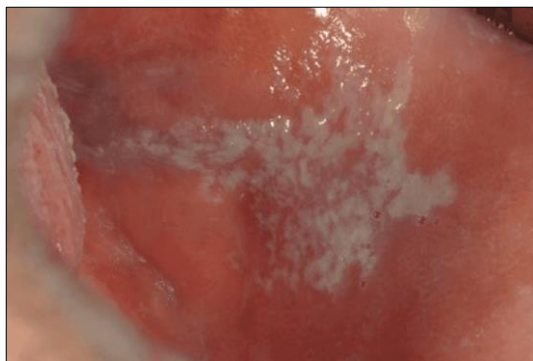
Among individuals with HIV, there are four different manifestations of oral candidiasis: pseudomembranous candidiasis (thrush), atrophic (erythematous) candidiasis, angular cheilitis (perleche) and rarely, hyperplastic candidiasis. Individuals with HIV who have either pseudomembranous or erythematous disease often complain of a burning sensation and altered taste.

**Pseudomembranous Candidiasis:** This form of candidiasis manifests as painless, creamy white plaques or patches that can be easily scraped off with a tongue depressor.

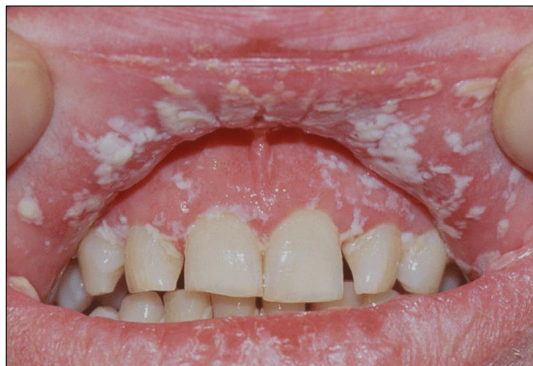Pseudomembranous candidiasis may involve any oral mucosal surface, including the palate, buccal mucosa, gingiva, and tongue (Fig 1).



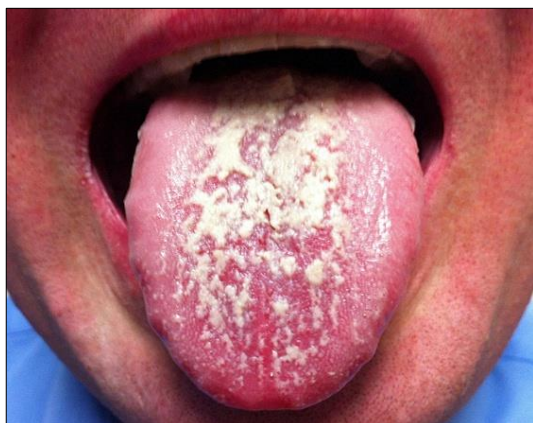**Fig 1A:** Pseudomembranous Candidiasis on Palate



**Fig 1B:** Pseudomembranous Candidiasis on Buccal Mucosa



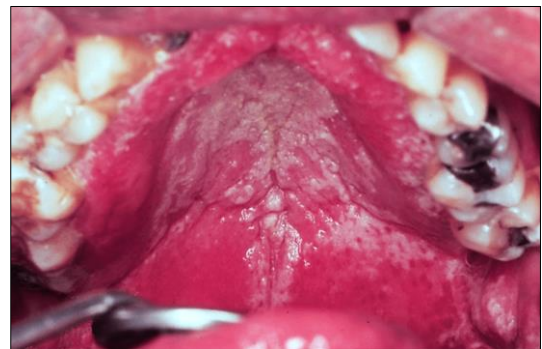
**Fig 1C:** Pseudomembranous Candidiasis on Gingiva (Gums) and Lips



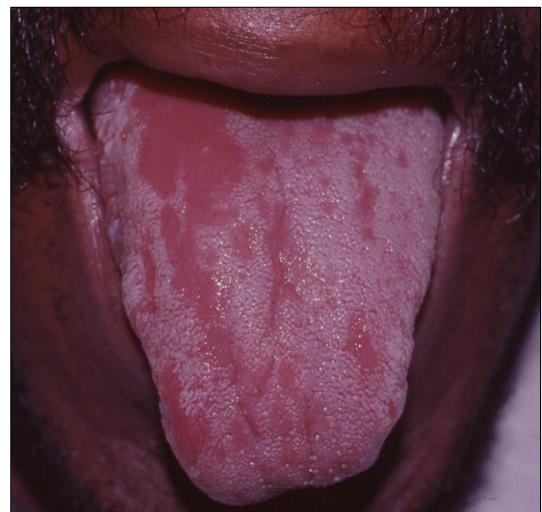**Fig 1D:** Pseudomembranous Candidiasis on Tongue

**Erythematous Candidiasis**

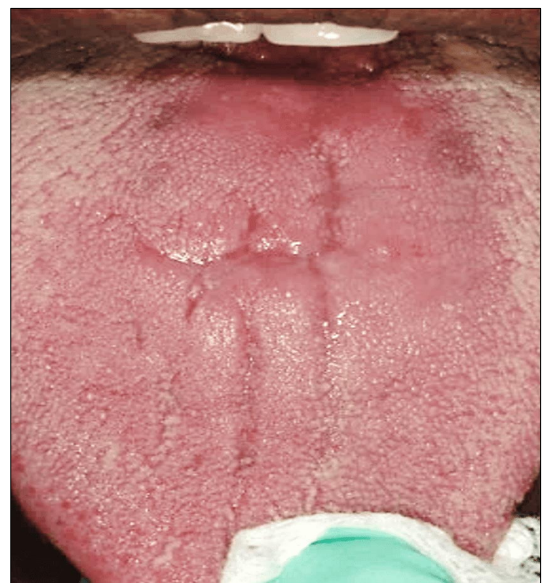
Erythematous candidiasis, which is less common than pseudomembranous candidiasis, typically presents as flat red patches most commonly on the hard palate and the dorsal surface of the tongue as areas of depapillation and fissuring (Fig 2).



**Fig 2A:** Erythematous Candidiasis on Palate



**Fig 2B:** Erythematous Candidiasis on Tongue

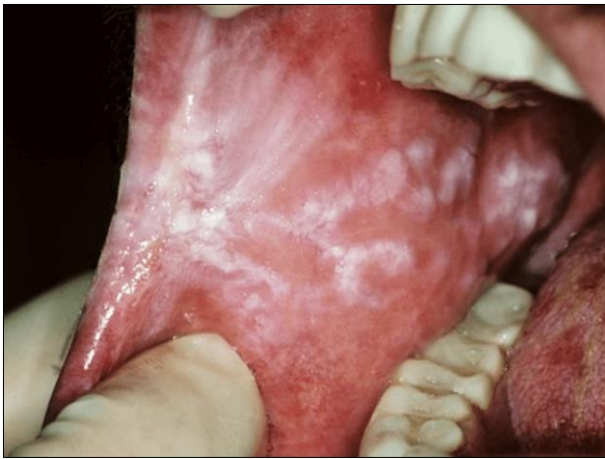

**Fig 2C:** Erythematous Candidiasis on Tongue with Fissuring

**Hyperplastic candidiasis**

This type of oral candidiasis is uncommon and may present as inflamed regions with a cobble stone appearance under

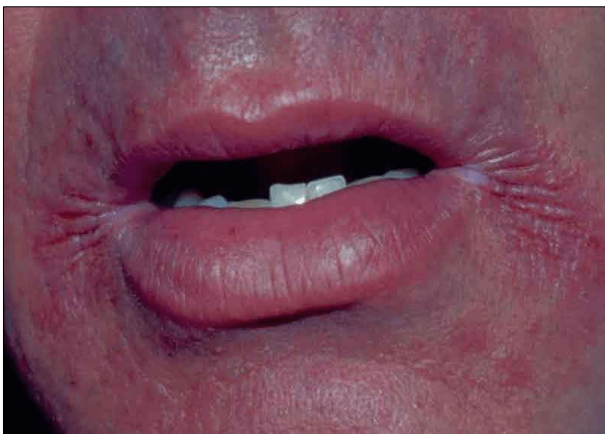dental prostheses or as well demarcated white plaques on buccal mucosa, inner commissures of the lips or lateral aspects of the tongue that do not scrape off (Fig 3).



**Fig 3:** Hyperplastic Candidiasis on Buccal Mucosa

#### Angular cheilitis

This form of oral candidiasis manifests as erythema and splitting of the corners of the mouth (Fig 4); if not treated, this can progress to a chronic, non-healing ulcer.



**Fig 4:** Angular Cheilitis

#### Diagnosis

A presumptive diagnosis of oropharyngeal candidiasis is based on typical clinical appearance or on a favorable response to an empiric trial of antifungal medication. A definitive diagnosis of oropharyngeal candidiasis requires obtaining a direct smear and performing a potassium hydroxide (KOH) wet mount, periodic acid-Schiff (PAS) stain, or Gram's stain and seeing characteristic yeasts. Fungal cultures are reserved for patients who do not respond to first-line therapy or for cases of suspected antifungal resistance.

#### Treatment

Episodic treatment of clinical episodes is strongly preferred over chronic suppressive therapy, mainly because of the risk of developing antifungal drug resistance with chronic therapy. Chronic suppressive therapy is not recommended unless the individual has frequent or severe recurrences of mucosal candidiasis. In addition, routine primary prophylaxis is not recommended because oral candidiasis has relatively low attributable morbidity and acute treatment is highly effective [5]. In the Adult and Adolescent OI

Guidelines, oral fluconazole is the drug of choice for treating oropharyngeal candidiasis based on its efficacy, convenience, and tolerance; the treatment duration is for 7 to 14 days, regardless of which type of medication is used [5].

#### Preferred Therapy

Oral fluconazole is not recommended for pregnant persons, especially those in the first trimester. Topical therapies include miconazole buccal tablets, clotrimazole lozenges (troche), miconazole mucoadhesive buccal tablets, nystatin suspension, nystatin lozenges (pastille), and a topical gentian violet application; topical therapy reduces the risk of systemic drug exposure and adverse events, but they are not as effective and thus all are considered alternative therapies.

#### Alternative Therapy

Alternative systemic therapy consists of either itraconazole oral solution or posaconazole oral solution.

#### Fluconazole-resistant candidiasis

Refractory oropharyngeal candidiasis in persons with HIV and advanced immunosuppression emerged in response to the widespread and frequent use of fluconazole; in earlier years of the epidemic, it occurred in approximately 5% of persons with HIV [6]. Studies have identified multiple risk factors for the development of fluconazole-resistant candidiasis, including greater number of fluconazole-treated episodes, longer median duration of fluconazole therapy, and advanced immunosuppression (especially a CD4 count less than 50 cells/mm<sup>3</sup>) [7]. In addition, the likelihood of fluconazole-resistant candidiasis depends on the *Candida* species causing the infection: most *C. albicans* species are susceptible to fluconazole whereas non-*albicans* species have variable resistance patterns to antifungal agents. A recently identified non-*albicans* species, *C. auris*, is remarkably resistant to all major antifungal drug classes and has shown a significant capacity to spread among healthcare facilities [8-10]. Although this organism has not been associated with oral infections in people with HIV, it could presumably infect [11] the oral mucosa. Thus, oropharyngeal candidiasis that is resistant to multiple types of treatment, should raise the possibility of *C. auris*, infection. For persons who have clinically refractory oropharyngeal candidiasis and/or azole-resistant candidiasis, expert consultation is advised.

#### Conclusion

It is essential that healthcare professionals have the power to identify, diagnose, and treat oral pathologies through clinical characteristics, etiological agents, and risk factors, both local and systemic.

#### References

1. Reznik DA. Oral manifestations of HIV disease. *Top HIV Med.* 2005 Dec-2006;13:143-8.
2. Bonacini M, Young T, Laine L. The causes of esophageal symptoms in human immunodeficiency virus infection. A prospective study of 110 patients. *Arch Intern Med.* 1991;151:1567-72.
3. Klein RS, Harris CA, Small CB, Moll B, Lesser M, Friedland GH. Oral candidiasis in high-risk patients as the initial manifestation of the acquired immunodeficiency syndrome. *N Engl J Med.* 1984;311:354-8.

4. Thompson GR 3<sup>rd</sup>, Patel PK, Kirkpatrick WR, *et al.* Oropharyngeal candidiasis in the era of antiretroviral therapy. *Oral Surg Oral Med Oral Pathol Oral Radiol Endod.* 2010;109:488-95.
5. Panel on Opportunistic Infections in Adults and Adolescents with HIV. Guidelines for the prevention and treatment of opportunistic infections in adults and adolescents with HIV: recommendations from the Centers for Disease Control and Prevention, the National Institutes of Health, and the HIV Medicine Association of the Infectious Diseases Society of America. *Candidiasis (mucocutaneous).* May 26, 2020.
6. Rex JH, Rinaldi MG, Pfaller MA. Resistance of *Candida* species to fluconazole. *Antimicrob Agents Chemother.* 1995;39:1-8.
7. Maenza JR, Keruly JC, Moore RD, Chaisson RE, Gallant JE. Risk factors for fluconazole-resistant candidiasis in HIV-infected patients. *J Infect Dis* 1996;173:219-25.
8. Ben-Ami R, Berman J, Novikov A, *et al.* Multidrug-Resistant *Candida haemulonii* and *C. auris*, Tel Aviv, Israel. *Emerg Infect Dis.* 2017;23:195-203.
9. Chowdhary A, Sharma C, Duggal S, *et al.* New clonal strain of *Candida auris*, Delhi, India. *Emerg Infect Dis.* 2013;19:1670-3.
10. Satoh K, Makimura K, Hasumi Y, Nishiyama Y, Uchida K, Yamaguchi H. *Candida auris* sp. Nov., a novel ascomycetous yeast isolated from the external ear canal of an inpatient in a Japanese hospital. *Microbiol Immunol.* 2009;53:41-4.
11. Pathirana RU, Friedman J, Norris HL, *et al.* Fluconazole-Resistant *Candida auris* Is Susceptible to Salivary Histatin 5 Killing and to Intrinsic Host Defenses. *Antimicrob Agents Chemother.* 2018;62:e01872-17.